

The Place of Thrombolysis in the Treatment of Peripheral Arterial Thrombosis

A French multidisciplinary expert panel met to discuss the place of thrombolysis for the treatment of peripheral arterial thrombosis in the modern setting.

**BY PATRICK FEUGIER, MD, PhD; ROMARIC LOFFROY, MD, PhD, FCIRSE;
JEAN PICQUET, MD, PhD; LUDOVIC BERGER, MD, PhD; ERIC DUCASSE, MD, PhD;
AND HERVÉ ROUSSEAU, MD, PhD**

Thrombolysis, an established and effective treatment for peripheral arterial thrombosis, has been popular for decades. During thrombolysis, administration of a thrombolytic drug destroys the blood clot. All currently available thrombolytic agents are plasminogen activators; they induce blood clot destruction by converting plasminogen into plasmin, an enzyme that cuts and destroys the fibrin polymer network that unites the thrombus. Because of this lytic action on the fibrin polymer network, thrombolytic agents are also called “fibrinolytic agents.”¹

ADMINISTRATION ROUTE AND INFUSION METHODS

In the early days of thrombolytic therapy, thrombolytic agents were commonly administered via a central route. Currently, however, this systemic administration route has been abandoned, except for certain specific indications. Today, thrombolytic agents are administered *in situ* during the arterial revascularization procedure, meaning that the drug is injected close to or directly into the thrombus. This evolution toward a local administration route was driven by improved efficacy, thanks to the increased local intrathrombus fibrinolysis, as well as a reduction in systemic bleeding complications.

There are several recognized methods for thrombolytic delivery: bolusing (lacing), continuous infusion, pulse-spray infusion, stepwise infusion, graded infusion, and enclosed infusion. The method that is most often used today is an intrathrombus high-dose bolus, followed by a medium-dose continuous infusion; it is the least complex protocol, simplifying the overall procedure, and at the same time is highly effective. The bolus method is the delivery of a single, highly concentrated dose of thrombolytic agent throughout the occlusion, in order to saturate the occluded vessel area with the drug. During the continuous infusion, the catheter

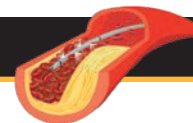
is connected to a pump, and a constant drug delivery is obtained (see page 10 for an example of a protocol).¹⁻³

THROMBOLYTIC AGENTS

Several thrombolytic agents are currently on the market, including streptokinase, urokinase, alteplase, tenecteplase, and reteplase. The indirect plasminogen activator, streptokinase, was the first agent used for intra-arterial thrombolysis, but its use has been mostly abandoned because of its lesser efficacy and its highly allergenic nature. The use of alteplase, reteplase, and tenecteplase for peripheral artery thrombosis in Europe is not very common, as these agents are not approved for this indication. On the other hand, urokinase is approved for this purpose and is available in most European countries. Moreover, urokinase has been reported to have a better safety profile than alteplase for the treatment of peripheral artery thrombosis.^{2,4,5}

MONOTHERAPY OR COMBINATION THERAPY WITH A MECHANICAL RECANALIZATION (PHARMACOMECHANICAL THROMBOLYSIS [PMT])?

Mechanical forces can be added to thrombolysis to reduce the therapy duration and improve efficacy on old thrombi. More and more endovascular thrombectomy devices are becoming commercially available, offering a wide variety of mechanical forces, including aspiration, rheolysis, rotational fragmentation, and ultrasounds. An example of a mechanical force frequently associated with thrombolysis in France is an attempt of thrombus aspiration before the start of the thrombolytic infusion. Attempting thrombus aspiration allows the bulk of the thrombus to lessen, thereby reducing treatment duration and the risk of distal embolization. An important downside of endovascular thrombectomy devices, however, is their high cost. Moreover, at the moment, few endovascular



thrombectomy devices are reimbursed in France and Belgium. A note of caution is warranted for these endovascular thrombectomy instruments, as the safety and efficacy has not been evaluated for all devices in randomized settings.¹

Thrombolysis can also be added to open surgery techniques to remove the residual thrombus or microemboli in the small arteries and vascular bed (see page 6 and Figure 1 for a proposed algorithm for the selection of the appropriate treatment according to the patient category).⁶

PROS AND CONS

Advantages

Thrombolysis offers several advantages in comparison to mechanical destruction of the thrombus, using endovascular thrombectomy devices or open surgery.

Nontraumatic. A key advantage of thrombolysis is that it does not damage the vessel wall. This is an important characteristic, as vessel injury provokes a thrombogenic endothelial environment, increasing the risk of thrombus recurrence.¹ The absence of vessel trauma is a unique asset of thrombolysis, as vessel damage is commonly reported after use of mechanical endovascular devices as well as open surgery. For example, thromboembolectomy with a Fogarty catheter (Edwards Lifesciences) is known to traumatize the vascular endothelium and induce potential vasospasm.⁷ For the more recent endovascular techniques, damage is frequently reported with arteriovenous fistula in 0% to 5% and vessel perforations in 4.8% to 10% of the cases treated with rotational endovascular devices.^{8,9}

Moreover, the radiography-documented positioning of the catheter combined with the non-aggressive nature of the thrombolytic infusion reduces the risk of adverse events encountered when using mechanical thrombus removal therapies, which are rather aggressive and “blind.” The use of thrombolysis has minimal risk of rupture of an underlying aneurysm or dislocation of an endoprosthesis—complications that are reported after thromboembolectomy with a Fogarty catheter.^{10,11}

This dissolution of the thrombus without inflicting further damage to the vessel wall allows the interventionist to bring the lesion back to the condition right before thrombosis and visualize the underlying pathology.¹² This permits the concomitant selective correction of the underlying lesion using other endovascular techniques (eg, balloon angioplasty or stents) without extensive vascular trauma, thereby eliminating the threat of rethrombosis.

Limited invasiveness. Because thrombolysis is administered via catheter, the invasiveness of the technique is limited to catheter insertion, and the procedure only requires local anesthesia. The fact that the interventionist does

not need to (re-)open or deeply anesthetize the patient is especially important for those who have undergone multiple operations or individuals with concomitant pathologies. Less cardiopulmonary adverse events have been reported for thrombolysis than for open surgery, which was associated with better patient survival in the thrombolysis group.^{13,14}

Another advantage of the limited invasive nature of thrombolysis is a reduction in wound infections in patients treated with thrombolysis in comparison to open surgery.¹⁴

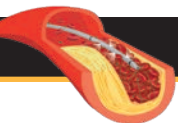
Penetration into the small vessels. Thrombolytic molecules have the capacity to permeate into the small vessels and vascular bed because of their small size. This is in contrast to open surgery techniques and mechanical endovascular techniques, for which penetration is limited to the diameter of surgical tools and catheters. The complete removal of the thrombus is key not only to restore the blood flow in the main vessel but also to remove the distal flow obstruction and reduce the risk of thrombus recurrence. For this reason, thrombolysis is often added after open surgery/mechanical thrombectomy devices, as it not only removes the residual thrombus in the large arteries but also removes the thrombus or microemboli (that have parted distally after the mechanical intervention) in the small arterioles and vascular bed.¹⁵

Disadvantages

On the other hand, thrombolysis also has some disadvantages.

Risk of bleeding. A disadvantage of thrombolysis that is inherent to its mechanism of action is the risk of bleeding. Therefore, a detailed examination of the patient is essential before the start of thrombolytic therapy to enable the exclusion of patients with contraindications to thrombolytic agents. This risk of bleeding depends on the dose of the thrombolytic agent that is being administered and is much less important for a single bolus injection (no significant increase in bleeding complications with a dose up to 500,000 IU urokinase administered as adjuvant to operative lower extremity revascularization¹⁶) than for a continuous infusion over several days.¹⁷ It is also important to note that the incidence of bleeding today is much lower than the incidence reported for administration via a central route in the literature from the 1980s to the 1990s, thanks to the local, directed infusion of the thrombolytic agent. Recent data from France show an incidence of intracranial bleeding of 0.4% for a protocol of a bolus plus continuous infusion of a medium dose of the thrombolytic agent (Feugier P, Picquet J, et al, unpublished data, 2018).

Treatment duration. The thrombolytic treatment dissolves the thrombus gradually, as the activated plasmin eats away



layer after layer of the fibrin network. Therefore, thrombolysis as monotherapy can take several hours or even up to a couple of days (depending on the dose/h of the infused thrombolytic agent and the size of the thrombus), during which close surveillance of the patient is required. It is important to note, however, that although it might take some time before the thrombus is completely dissolved, oxygen and nutrients will be able to pass the partially dissolved occlusion much sooner.

Most effective on a fresh thrombus. In order for the thrombolytic agent to break down the fibrin network, it has to be able to penetrate into the thrombus. This penetration is much easier in a fresh thrombus (ideally < 15 days¹⁸ but up to 30 days¹⁹) than in a thrombus that is old, established, and has a very organized and hard structure. For the removal of old thrombus, it is best to combine the thrombolytic agent with a mechanical thrombus removal strategy.

Microembolization. During thrombolysis, as during mechanical thrombectomy techniques (eg, ballooning an arterial stenosis with fresh clot), it is possible for small parts of the thrombus to break off and part distally, where they block the arterial collateral vessels or small distal vessels (occurs in 1%–15% for catheter-directed thrombolysis and 0%–14% for mechanical thrombectomy).^{1,3} These microemboli can be very painful for the patient, because they cause an actuation of ischemia that must be managed. However, these distal microemboli can be easily dissolved by further continuation of the thrombolysis.

Costs. A disadvantage of thrombolysis from an economic point of view is the cost of the thrombolytic agent itself as well as the necessity of close follow-up on a high- or medium-surveillance unit. The degree of this disadvantage depends on the dose of thrombolytic used and the treatment duration.

Conclusion. These advantages and disadvantages underline the importance of patient selection.

PATIENT SELECTION

How is the diagnosis of peripheral artery thrombosis made?

The diagnosis of peripheral artery thrombosis is made using a Doppler echocardiogram, a CT angiography scan, or angiography. Right before the intervention, angiography is performed to determine the precise location, actual length, and morphology of the lesion, as well as the collateral flow, inflow, and distal runoff vessels.

How are patients with acute limb ischemia classified?

A classification system was defined by the Society for Vascular Surgery and updated by the TransAtlantic Inter-Society Consensus II guidelines in 2007 for describing the degree of acute limb ischemia (this classification is sometimes also referred to as the *Rutherford classification for acute limb ischemia*—see Table 1).²⁰ The main objective of this categorization is to stratify the acuity of limb ischemia into defined groups for decision-making purposes.

Which type of patients will benefit from thrombolysis?

In general, all patients without contraindications can benefit from thrombolysis; however, the severity of the ischemia will determine whether treatment can be thrombolysis as monotherapy or whether it has to be associated with mechanical endovascular thrombectomy or open surgery (combination therapy) (Figure 1).

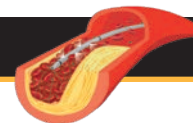
The selection of the type of therapy that will be most advantageous for the patient is based on the advantages and disadvantages of the therapeutic strategies, as previously mentioned.

Patients who will benefit from catheter-directed thrombolysis have the following characteristics: (1) recent thrombosis (ideally < 15 days¹⁸; up to 30 days¹⁹), (2) no sensory-motor deficit (acute limb ischemia category I and IIa) so there is time to intervene, and (3) no

TABLE 1. CLASSIFICATION OF ACUTE LIMB ISCHEMIA²⁰

Category	Definition	Prognosis of the Limb	Physical Examination		Doppler Signals	
			Sensory Loss	Muscle Weakness	Arterial	Venous
I	Viable	Not immediately threatened	None	None	Audible	Audible
II	Threatened					
IIa	Marginally	Salvageable with prompt treatment	Minimal (toes)	None	Often inaudible	Audible
IIb	Immediately	Salvageable with immediate treatment	More than toes, pain at rest	Mild to moderate	Usually audible	Audible
III	Irreversible	Major permanent tissue loss	Anesthetic	Paralysis	Inaudible	Inaudible

Reprinted from Journal of Vascular Surgery, 26, Rutherford RB, Baker JD, Ernst C, et al, Recommended standards for reports dealing with lower extremity ischemia: revised version, 517-538, 1997, with permission from Elsevier.



contraindications for thrombolytic therapy (see paragraph on contraindications).

For the patients with an older thrombus or a sensory-motor deficit (acute limb ischemia category IIb), mechanical endovascular thrombectomy or open surgery is recommended, as the ischemia is very acute and has to be resolved as quickly as possible. Furthermore, we recommend combining these techniques with the administration of a thrombolytic agent (bolus \pm continuous infusion) to complete thrombus removal of the entire vascular bed.

Which type of occluded artery can be treated by thrombolysis?

Thrombolysis is a good therapeutic option for all types of vessels, as it has been shown to be effective on native vessels or prosthetic bypass grafts and endoprostheses.

Does the anatomic position of the thrombus play a role?

Thanks to the endovascular approach, avoiding sometimes challenging surgical incisions, thrombolysis can be used to treat thrombi in particularly interesting locations. Therefore, thrombolysis is a particularly interesting solution to retain in the therapeutic arsenal for peripheral arteries (eg, distal arteries of the hand or foot and visceral arteries, including renal and mesenteric arteries).

Which are the most encountered contraindications for thrombolytic therapy?

As a rule, most contraindications to thrombolysis are aimed at minimizing the risk of bleeding; a nonexhaustive list of the absolute and relative contraindications can be found in Table 2.

Absolute contraindications to thrombolysis include active or recent internal bleeding, uncontrollable changes in hemostasis, intracranial neoplasm, or recent (within 2 months) cerebrovascular events or craniotomy. Relative contraindications to thrombolysis include recent major surgery, organ biopsy, trauma, gastrointestinal bleeding, pregnancy, postpartum period, uncontrolled hypertension, and diabetic hemorrhagic retinopathy.^{3,22} Within this context, it is important to note that the risk of bleeding strongly depends on the dose of thrombolytic agent infused and the duration of infusion. These contraindications will therefore be more relative for the injection of a bolus of thrombolytic agent versus a continuous infusion during several hours or days. In general, it is key that the prescribing doctor always weighs the risk of bleeding against the benefits of the thrombolytic treatment.

THROMBOLYTIC PROCEDURE: PRACTICAL STEPS

(1) Preprocedural Laboratory Investigations

Blood work before the start of treatment includes blood count, platelets, a full coagulation profile (prothrombin

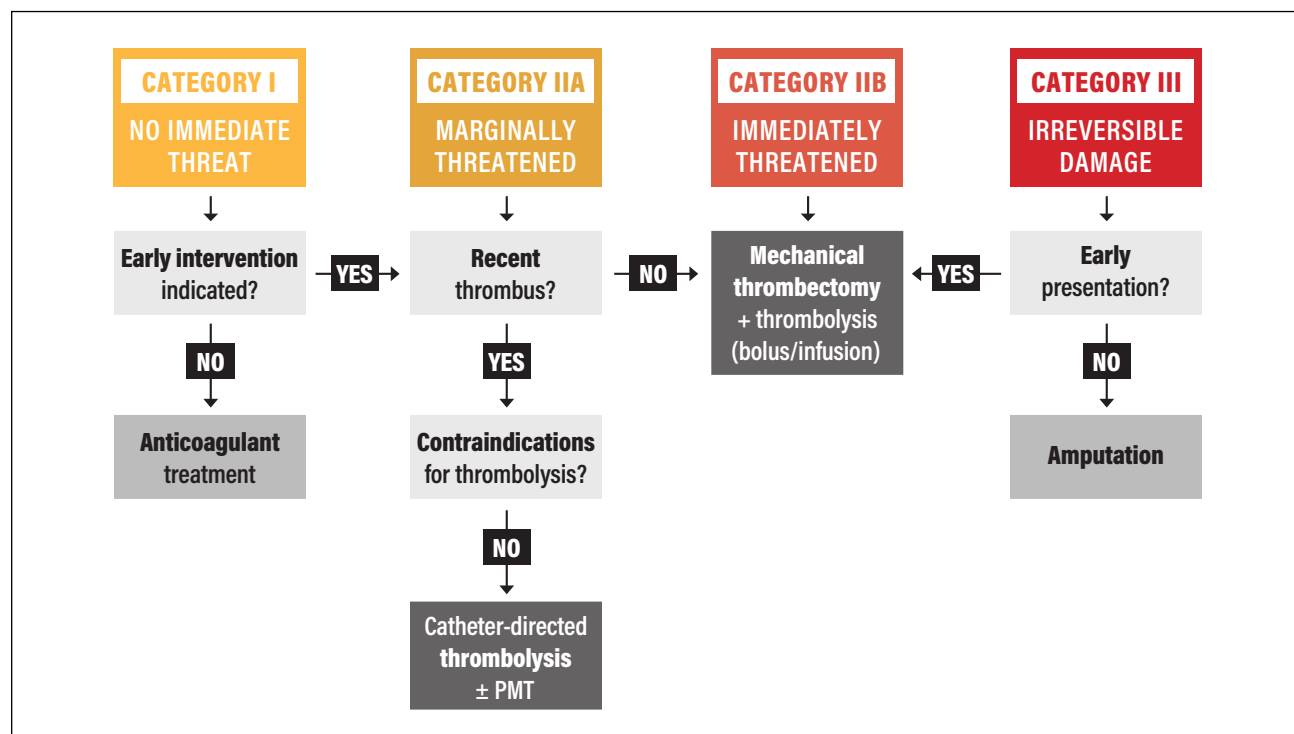
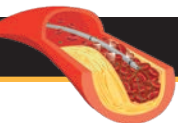


Figure 1. Treatment-decision algorithm for patients with acute limb ischemia.^{1,21} Abbreviation: PMT, pharmacomechanical thrombolysis.



time and/or international normalized ratio, activated partial thromboplastin time [aPTT], and fibrinogen levels), and renal and hepatic function.

(2) Vascular Access Site

The choice of puncture site should be consistent with lesion location and the patient's anatomical particularities. For the lower limb, the vascular access site is most commonly retrograde, via the contralateral common femoral artery, allowing access to the contralateral iliac axis or the lower limb by crossover catheterization. In case of distal arterial occlusion, however, antegrade femoral puncture is preferred in a patient in whom homolateral puncture is feasible. It is also possible to consider inserting the catheter for thrombolytic treatment by brachial or popliteal routes, but this remains an exception.

A single arterial wall puncture is needed. We recommend performing this puncture under ultrasonography. Only the anterior arterial wall should be punctured to avoid hematoma or false aneurysms of the posterior wall. After sheath placement, the interventionist secures vascular access by skin fixation.

(3) Angiography

Before revascularization, high-quality diagnostic angiography is performed to assess the inflow and outflow arteries as well as the nature and length of thrombosis.

(4) Guidewire Traversal Test

The guidewire traversal test is an important parameter that, if successful, predicts the positive outcome of catheter-directed thrombolysis. If the thrombus can be crossed with the guidewire, this indicates that the thrombus is recent (fresh) and not yet older and highly organized.¹ Moreover, this test allows the interventionist to create a small channel inside the thrombus to facilitate fibrinolysis.

(5) Thrombolytic Infusion

After guidewire placement, a catheter (preferably a multi-side hole catheter) is inserted into the thrombus, and the thrombolytic therapy can be initiated. It is important to note that the catheter should be positioned in or close to the proximal end of the thrombus, but that one cannot pass the thrombus completely with the catheter, as this would lead to a systemic administration. After the first period of fibrinolysis and according to the results of the angiographic control, the interventionist can advance the catheter further into the thrombus (see [6] Patient Monitoring).

Concomitant administration of anticoagulant therapy?

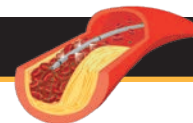
Treating patients concomitantly with heparin is recommended to prevent pericatheter thrombosis and rethrombosis of the treated vessel. In practice, heparin can be infused via the arterial sheath or via a peripheral venous infusion. As heparin has been shown to increase bleeding complications, it is now standard to use a "subtherapeutic" dose that produces only mild prolongation of the aPTT (see example of a protocol on page 10).

(6) Patient Monitoring

Close medical surveillance of the patient during catheter-directed thrombolysis is essential due to the risk of bleeding complications. Patients need to be monitored carefully in the intensive care unit or the vascular ward. Nurses are key to patient monitoring, as they must closely watch their clinical status. These duties include regular monitoring of the patient's condition: general well-being, blood pressure, bruises, bleeding at the puncture site, pain, and the appearance of the thrombosed limb. Every 4 hours, a blood analysis has to be performed including blood count, fibrinogen, aPTT, and/or anti-factor Xa assay. The fibrinogen levels of this analysis are used to adapt the urokinase dosage, and the aPTT and/or anti-Xa values are used to adapt the heparin doses. Regular angiographic controls are performed

TABLE 2. CONTRAINDICATIONS FOR THROMBOLYTIC THERAPY^{3,22}

Absolute
Active or recent internal bleeding
Recent stroke (arbitrary guidelines: TIA < 2 months or CVA < 6–12 months)
Intracranial neoplasm or recent (within 2 months) craniotomy
Protruding mobile left heart thrombus
Uncontrollable changes in the hemostasis
Irreversible limb ischemia (severe sensory deficits and muscle rigor)
Relative
Recent (10–14 days) major surgery, including biopsy
Recent (10–14 days) trauma, puncture of a noncompressible vessel
Recent (10–14 days) hematuria or gastrointestinal bleeding
Severe uncontrolled high blood pressure
Endocarditis or pericarditis
Coagulopathy
Pregnancy and the postpartum period
Severe cerebrovascular disease
Diabetic hemorrhagic retinopathy
Minor
Recent CPR
Thrombocytes < 100,000/mm ³ , level of prothrombin < 50%
Severe hepatic or renal insufficiency
Abbreviations: CPR, cardiopulmonary resuscitation; CVA, cerebrovascular accident; TIA, transient ischemic attack.



in order to follow the dissolution of the thrombus and to allow catheter repositioning if required. The timing of the angiographic controls depends on the protocol and the pathology treated and varies from a repeat angiogram every 4 to 12 hours to a daily angiographic control.

What if the pain increases during the treatment? Sometimes at the beginning of the thrombolytic therapy, the pain intensifies. This increase in pain is generally caused by small parts of the thrombus that are liberated from the dissolving thrombus and distally obstruct small arteries or collateral arteries, thereby causing ischemic pain. This pain is transient, as these small microemboli will dissolve upon further administration of the thrombolytic agent. Pain by itself after fibrinolysis initiation is actually not an argument to stop the fibrinolysis. Administration of the appropriate pain medication is indicated.

(7) Correction of the Underlying Lesion if Applicable

Once the flow is restored, angiography is performed to detect any underlying lesion, allowing for the immediate, appropriate, and selective lesion correction with catheter-based techniques (most commonly angioplasty with or without stenting) or open revascularization.

CONCLUSION

Thrombolysis has several valuable characteristics that offer a benefit in the treatment of patients with peripheral arterial thrombosis. Depending on the severity of the ischemia and the age of the thrombus, thrombolysis will be administered either as monotherapy or in combination with mechanical endovascular thrombectomy techniques or open surgery.

The selective, non-aggressive nature of thrombolysis constitutes a key advantage, because it does not aggravate the underlying vascular pathology and permits for the selective correction of the underlying lesion, thereby minimizing the risk of rethrombosis. Although thrombolysis has a higher risk of bleeding complications compared with

open surgery, the risk of cardiopulmonary adverse events is much less important, resulting in an ameliorated survival rate for thrombolysis.

The unique ability of thrombolytics to reach even the smallest vessels explains the value of adding thrombolysis to a mechanical endovascular thrombectomy procedure or open surgery. The further removal of the thrombus in small arteries and the vascular bed improves the clinical outcome and reduces thrombus reoccurrence.

In conclusion, we believe that thrombolytic therapy should be a part of the vascular team's armamentarium in their mission to safely and successfully treat patients with peripheral arterial thrombosis. ■

1. Karnabatidis D, Spiliopoulos S, Tsetis D, Siablis D. Quality improvement guidelines for percutaneous catheter-directed intra-arterial thrombolysis and mechanical thrombectomy for acute lower-limb ischemia. *Cardiovasc Interv Radiol*. 2011;34:1123-1236.
2. Branco BC, Montero-Baker MF, Mills JL Sr. The pros and cons of endovascular and open surgical treatments for patients with acute limb ischemia. *J Cardiovasc Surg*. 2015;56:401-407.
3. Mauro MK, Murphy KPJ, Murphy KR, et al. Image-Guided Interventions: Expert Radiology Series (Expert Consult). 2nd ed. Philadelphia: Elsevier Saunders; 2014.
4. Ouriel K, Kandarpa K. Safety of thrombolytic therapy with urokinase or recombinant tissue plasminogen activator for peripheral arterial occlusion: a comprehensive compilation of published work. *J Endovasc Ther*. 2004;11:436-446.
5. Ouriel K, Kaul AF, Leonard MC. Clinical and economic outcomes in thrombolytic treatment of peripheral arterial occlusive disease and deep venous thrombosis. *J Vasc Surg*. 2004;40: 971-977.
6. Comerota AJ, Sidhu R. Can intraoperative thrombolytic therapy assist with the management of acute limb ischemia? *Semin Vasc Surg*. 2009;22:47-51.
7. Van DH, Boesmans E, Defraigne JO. [Acute limb ischemia]. *Rev Med Liege*. 2018;73:304-311.
8. Berczi V, Deutschmann HA, Schedlbauer P, et al. Early experience and midterm follow-up results with a new, rotational thrombectomy catheter. *Cardiovasc Interv Radiol*. 2002;25:275-281.
9. Lagana D, Carrafiello G, Lumia D, et al. Recanalisation of thrombotic arterial occlusions with rotational thrombectomy. *La Radiologia Medica*. 2011;116:932-944.
10. Dainko EA. Complications of the use of the Fogarty balloon catheter. *Arch Surg*. 1972;105:79-82.
11. Schweitzer DL, Aguam AS, Wilder JR. Complications encountered during arterial embolectomy with the Fogarty balloon catheter. *Vasc Surg*. 1976;10:144-156.
12. Morrison HL. Catheter-directed thrombolysis for acute limb ischemia. *Semin Intervent Radiol* 2006;23:258-269.
13. Ouriel K, Shortell CK, DeWeese JA, et al. A comparison of thrombolytic therapy with operative revascularization in the initial treatment of acute peripheral arterial ischemia. *J Vasc Surg*. 1994;19:1021-1030.
14. Genovese EA, Chaer RA, Taha AG, et al. Risk factors for long-term mortality and amputation after open and endovascular treatment of acute limb ischemia. *Ann Vasc Surg*. 2016;30:82-92.
15. Comerota AJ, Sidhu R. Can intraoperative thrombolytic therapy assist with the management of acute limb ischemia? *Semin Vasc Surg*. 2009;22:47-51.
16. Comerota AJ, Rao AK, Thom RC, et al. A prospective, randomized, blinded, and placebo-controlled trial of intraoperative intra-arterial urokinase infusion during lower extremity revascularization. Regional and systemic effects. *Ann Surg*. 1993;218:534-541; discussion 541-543.
17. Darwood R, Berridge DC, Kessel DO, et al. Surgery versus thrombolysis for initial management of acute limb ischemia. *Cochrane Database Syst Rev*. 2018;8:CD002784.
18. Results of a prospective randomized trial evaluating surgery versus thrombolysis for ischemia of the lower extremity. The STILE trial. *Ann Surg*. 1994;220:251-266; discussion 266-268.
19. Berridge DC, Kessel DO, Robertson I. Surgery versus thrombolysis for initial management of acute limb ischaemia. *Cochrane Database Syst Rev*. 2013; CD002784.
20. Norgren L, Hiatt WR, Dormandy JA, et al; TASC II Working Group. Inter-society consensus for the management of peripheral arterial disease (TASC II). *J Vasc Surg*. 2007;45 Suppl S:S5-67.
21. Rutherford RB. Clinical staging of acute limb ischemia as the basis for choice of revascularization method: when and how to intervene. *Semin Vasc Surg*. 2009;22:5-9.
22. Federal Agency for Medicines and Health Products website. <https://www.famhp.be/en>. Updated October 17, 2018. Accessed October, 2018.